

Open Access **Original Article**

Intranipple injection with methylene blue for tracing axillary sentinel lymph nodes in rats: A preliminary feasibility study

Fengjiang Qu^{1,*}, Di Wu^{2,*}, Zhimin Fan^{2,*}, Chenyang Hu^{2,*},
Jinxu Ma^{2,*}, Stefanos Zervoudis^{3,4,5}, Xiaozhen Wang^{2,*}

¹ Department of Emergency Surgery, The First Hospital of Jilin University, No. 1 Xinmin Street, Changchun, Jilin Province, China
Department of Breast Surgery

² General Surgery Center, Breast Surgery Department, The First Hospital of Jilin University, No. 1 Xinmin Street, Changchun, Jilin Province, China

³ Rea Hospital, Athens, Greece

⁴ University of West Attica, Athens, Greece

⁵ University of Ioannina, Ioannina, Greece

*Correspondence: qufj20@mails.jlu.edu.cn; Di-Wu@jlu.edu.cn; fanzm@jlu.edu.cn; cyhu19@mails.jlu.edu.cn; majinxu1998@163.com; wxzhen@jlu.edu.cn

Keywords: Intranipple injection, sentinel lymph node biopsy

Citation: F. Qu, D. Wu, Z. Fan, C. Hu, J. Ma, S. Zervoudis, X. Wang. Intranipple injection with methylene blue for tracing axillary sentinel lymph nodes in rats: A preliminary feasibility study. *Rev. Clin. Pharmacol. Pharmacokinet. Int. Ed.*, 2023, 37, 3, 123-128. <https://doi.org/10.61873/MVVA6586>

Received: 13 December 2023
Reviewed: 20 December 2023
Accepted: 26 December 2023
Published: 28 December 2023

Publisher's Note: PHARMAKON-Press stays neutral with regard to jurisdictional claims in published maps and institutional affiliations.



Copyright: © 2023 by the authors.
Licensee PHARMAKON- Press, Athens, Greece.
This article is an open access article distributed under the terms and conditions of the Creative Commons Attribution (CC BY) license (<http://creativecommons.org/licenses/by/4.0/>).

Corresponding author: Prof. Stefanos Zervoudis MD, PhD, Rea Hospital, 383 Syggrou Avenue. Palaio Faliro GR-17564, Greece. Tel: +306944308777.
Email: szervoud@otenet.gr; szervoudis@uniwa.gr

Abstract

Background and purpose: Investigate the feasibility of intranipple injection (INN) of methylene blue dye (MB) for tracing the axillary sentinel lymph node (SLN) in rats, to provide different injection methods for finding SLN injection tracers and offer an experimental basis for specific localization of SLN.

Methods: Eleven Sprague-Dawley female rats with body masses of 150-400g. Ten rats were randomly selected to use the third pair of mammary glands as the tracer injection site, and the left side was injected with MB (0.05 mL, 1% concentration) by intracutaneous injection of areola (IAA), while the right side was injected with MB (0.05 mL, 1% concentration) by INN. After 5 minutes, the rats were dislocated and dissected, and the blue-stained SLNs were found and recorded. The effectiveness evaluation was based on the number and rate of detection of SLNs as indicators, and the differences between the indicators of the two injection methods of IAA and INN were compared and analyzed. The

safety evaluation was based on whether the nipple showed blood flow disorders and necrosis after MB injection by INN in the remaining 1 rat as the criteria. The data were stored and analyzed using Microsoft Excel and SPSS 25.0 statistical software. Non-normally distributed measurement data were expressed as M (Q1, Q3) and compared by rank sum test, and count data were expressed as cases or percentages and compared by χ^2 test. $p < 0.05$ was considered a statistically significant difference.

Results: (i) 100% (10/10) detection rate of SLNs by applying MB to both INN and IAA modalities; (ii) median number of SLNs detection was 2.0 (1.0, 2.0) vs. 1.5 (1.0, 2.0) for INN and IAA, respectively ($P=0.66$), and the difference was not statistically significant; (iii) No nipple necrosis was observed for 4 consecutive days after INN with MB.

Conclusion: Tracer detection of SLNs by INN injection in rats is feasible, and the detection rate of SLNs by INN is the same as that of IAA; there is no significant difference in the median number of detected SLNs between the two injection methods. No nipple necrosis was observed after INN with MB.

INTRODUCTION

Sentinel lymph node biopsy (SLNB) can accurately predict axillary status and avoid complications such as upper limb edema, sensory and functional impairment due to axillary lymph node dissection (ALND), which has now become the standard procedure for axillary evaluation of clinical lymph node negative breast cancer (1, 2, 3). The choice of injection site is one of the key factors for the success of SLNB. In the past, it was thought that SLN was the first lymph node to be invaded when the tumor metastasized, and thus the tumor substance or surrounding tissue was often used for injection. With the in-depth study of breast lymphatic drainage found that SLN is the first station lymph node of the whole breast lymphatic return, and the lymphatic system in the nipple areola area is densely reticulated and easier to inject and perform lymphatic vessel mapping, so IAA is now often used (4). Based on the above theoretical basis, Zervoudis performed the first clinical trial of SLNB using INN of patent blue dye, which proved to have the advantages of safety, fixed location and high SLN detection rate (5). Therefore, we present a basic experimental study in which the

currently used tracer methylene blue is taken by INN to trap SLN in adult female rats and compared with IAA to support whether this technique is feasible and easy to perform.

1. MATERIALS AND METHODS

1.1 Experimental Animals

Sprague-Dawley rats, 150-400 g, females, 60-120 days, clean grade, were purchased from Xinda Animal Farm, Gongzhuling City, and housed in the clean animal room of the laboratory of the School of Pharmacy, Jilin University.

1.2 Main Experimental Reagents and Equipment

Methylene blue injection (20mg, 1%, 2mL Jichuan Pharmaceutical Group Co., Ltd.); chloral hydrate (configuration of experimental pharmacology and toxicology laboratory, School of Pharmacy, Jilin University); digital camera (self-provided); surgical instruments such as scalpel, ophthalmic scissors, hemostatic forceps, forceps, large-headed needle, medical gloves (provided by the laboratory of the College of Pharmacy, Jilin University); 1mL, 2mL, 5mL, 10mL syringes (provided by the laboratory of the College of Pharmacy, Jilin University); surgical operating table (provided by the laboratory of the College of Pharmacy, Jilin University).

1.3 Definition of Rat Anterior Sentinel Lymph Nodes

The animal model of rat forelimb SLN established in this study is simple to set up and based on the theory of W. Van den Broeck et al (6) study, the forelimb lymph nodes (axillary and para-axillary lymph nodes) of rats were defined as SLN of mammary lymphatic drainage.

1.4 Experimental Procedure

(1) 10 of 11 rats were randomly selected, and each rat was anesthetized by intraperitoneal injection of 10% chloral hydrate at 0.4 mL/100g body mass, and after anesthesia took effect for about 10 min, the rats were fixed in supine position on the operating table, and the third pair of breast area on both sides of the rats was dehaired with an electric razor;
(2) the third pair of breast was selected as the site of MB injection, and the left side was injected by IAA and the right side by INN with MB 0.05mL (1% concentration);

(3) cervical dislocation and dissection of the rat's axillary, and find the blue-stained lymph nodes and record the number;
 (4) the remaining 1 rat was injected with MB 0.05mL (1% concentration) by INN, and the nipple were monitored daily for blood flow disorders and necrosis for 4 consecutive days.

1.5 Evaluation Indexes

Validity evaluation; number of SLNs detected, SLNB detection rate, SLNB detection rate = number of rats in which tracer aggregated SLNs could be detected/total number of rats in the experimental group.

Safety evaluation: whether the rats showed blood flow disorders and necrosis of the papillae after MB injection by INN method.

1.6 Statistical Methods

Data were stored and analyzed using Microsoft Excel and SPSS 26.0 statistical software. Non-normally distributed measures were expressed as M (Q1, Q3) and compared using the rank sum test, and count data were expressed as cases or percentages and compared using the χ^2 test. $p < 0.05$ was considered a statistically significant difference.

1.7 Ethical Approval

This study was approved by the Ethics Committee of the First Hospital of Jilin University (No. 0020 of 2021).

2. EXPERIMENTAL RESULTS

2.1 Efficacy Evaluation

2.1.1 Comparison of the success rate of SLN detection after INN and IAA injection of MB

The success rate of SLN detection in 10 rats after MB injection by either INN or IAA was 100% (10/10), and the detection success rate was the same for both injection methods (Table 1).

2.1.2 Comparison of the number of SLN detection after INN and IAA injection of MB

The specific numbers of SLN in 10 rats injected with MB tracing by both injection methods are shown in Table 2, and the axillary anatomy and SLNs detection are shown in Figure 1.

The median number of sentinel lymph nodes detected in IAA vs INN was 1.5 (1.0,2.0) vs 2.0 (1.0,2.0) (P=0.66), and the differences were not statistically significant, as shown in Table 3.

Table 1. Success rate of SLN detection after INN and IAA injection of MB

	IAA	INN
MB	10/10 (100%)	10/10 (100%)

Table 2. The specific numbers of SLNs in 10 rats injected with MB after INN and IAA

Serial number	weight (g)	Number of SLNs detection (pieces)	
		IAA	INN
1	246	1	1
2	251	2	2
3	236	1	2
4	254	2	2
5	232	2	1
6	232	1	2
7	232	1	2
8	277	1	1
9	285	2	2
10	248	2	1

Table 3. Comparison of the number of SLN detections after INN and IAA injection of MB

	IAA	INN	Z	P
MB	1.5 (1.0,2.0)	2.0 (1.0,2.0)	-0.438	0.66

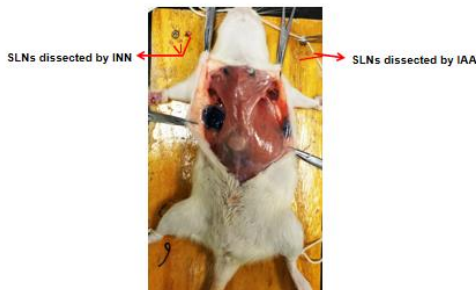


Figure 1 axillary anatomy and SLNs detection after MB injection

2.2 Safety evaluation: the situation of the nipple after MB injection by INN method

After the injection of MB by INN method, the rats were observed for 4 consecutive days to observe the blood flow of the papillae and whether necrosis occurred, and the overall process of papillae did not show blood flow obstruction and necrosis, and the rats were in good condition (Figure 2).

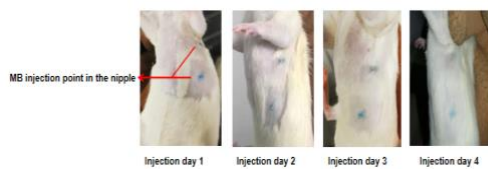

Figure 2 Papillary blood flow and skin condition after MB injection by INN in rats

3. DISCUSSION

3.1 Anatomical basis of the lymphatic system of the breast and the theoretical basis of SLNB by INN of tracer

The theoretical study on the anatomy of lymphatic drainage in the nipple region can be traced back to 1786 as described in the text of Cruikshank's published book: he (7) accidentally discovered mercury-filled breast lymphatic ducts after injecting mercury into the nipple ducts of a pregnant woman's cadaver. Although this was the first experimental report to demonstrate nipple-lymphatic duct intercommunication using injected liquid metal, Cruikshank did not diagram this finding to support it.

In 1874, Sappey was inspired by Cruikshank's

experimental technique (7) and applied the same procedure to inject mercury into the dermis of an adult cadaver with a very thin epidermis to investigate the distribution of superficial lymphatic vessels in the cadaver and their path of return. In his study, he found that the lymphatic vessels of the upper cadaver always flowed into the ipsilateral axillary area; the subareolar plexus of the nipple was the location of the lymphatic vessels of the breast, and the mercury in the lymphatic vessels eventually flowed to the axillary area through the lymphatic collecting ducts. Although not the result of a large overview study, this theory became the theoretical basis for the single-tracer method of dye injection in the areola area and the double-tracer method of combining radioisotopes for lymph node localization, as well as the theoretical basis for SLNB in breast cancer a century later (8). Of course, the above results are based on the results of non-breast cancer autopsy studies, but they are an important guide for our cognition of breast lymphatic vessels.

In 1959, Turner-Warwick injected Prussian blue iron or radioisotope gold (Au198) (9) into the patient's body during surgery for breast cancer patients to photographically and radiologically study the collecting lymphatics and to trace the lymphatic return characteristics at the cancer site. He found that lymph from all quadrants of the breast drained to the axillary and internal breast lymph nodes or to the posterior intercostal lymph nodes; the lymphatic pathway at the site of the breast tumor also passed directly to the axillary lymph nodes. This finding was confirmed by Hiroo Suami, (10) who in 2007 injected a mixture of hydrogen peroxide and lead oxide into 24 breasts of 14 fresh cadavers (5 males and 9 females) to examine the lymphatic vessels and perform cross-sections and radiographs to generate three-dimensional images to trace the path of the lymphatic collecting vessels from the external periphery to the primary tracer lymph nodes, whose results showed that the lymphatic collecting ducts were evenly distributed in the upper part of the anterior trunk and drained radially to the axillary lymph nodes. Some lymphatic ducts pass directly through the breast, while others pass through the internal breast ducts, with no significant differences between men and women. Cross-sectional radiographs of female specimens show that the lymphatic vessels follow a "wave-like" path through the superficial layers of the breast subcutaneous tissue. In the breast region, most of the collecting lymphatics were located between the breast tissue and the skin of the breast; some crossed the breast tissue itself; and finally all collecting

lymphatics converged to the axillary lymph nodes. It was verified that the axillary sentinel lymph node collects lymph from almost the entire breast, in most cases more than one sentinel lymph node. Although the surgical science has advanced enough, the anatomical knowledge about the lymphatic drainage of the breast has not advanced. Our current anatomical knowledge of the breast lymphatics still relies on the theory of Sappey, Poirer and Cuneo that the lymphatics deep in the areolar region of the nipple are different from those in other areas around the breast. Microscopy shows a dense network of lymphatic vessels and anterior lymphatic collecting ducts in the dermis of the areolar region, a structure that may be Sappey's reticular plexus; therefore, it is possible that dye injected subcutaneously into the breast would not be absorbed by the lymphatic ducts because the nipple-areolar region is the anatomical site with the highest concentration of lymphatic ducts. Therefore, the concept of axillary SLN not only draining lymph from the tumor area but also receiving lymphatic return from the whole breast revolutionized the knowledge of scholars, and thus shifted the tracer injection site from the tumor area to the areolar area where lymphatic vessels are abundant, but did not practice the INN method.

A 2012 study (5) reported the results of a multicenter study of INN of patent blue dye in breast cancer patients, which validated the feasibility of INN of tracer with the advantages of safety, fixed location, high SLN detection rate of 92.5% , sensitivity of 95.0%; as well as ease of operation, standardized injection site and without no local nipple infection or wound complications were observed. Therefore, there is a sound theoretical basis for adopting INN for SLNB, which is feasible from the anatomical point of view and lays the foundation for our experiment.

3.2 Analysis of the detection of SLNs by injecting MB in INN mode

Our experimental results showed that both IAA and INN injection of MB were feasible for the detection of SLNs. Although the difference in the number of SLNs detected by the two injection methods was not statistically significant, the median number of entries was higher in INN than in IAA, indicating that more SLNs could be detected in INN because there is a rich and dense lymphatic vascular network in the papillary area, with a diameter of 20-70 μm , and a tracer of comparable molecular diameter can be rapidly

diffused to the intradermal lymphatic collecting ducts and subdermal lymphatic ducts and then converge into the axillary lymphatic tissue after injection through the nipple. The lymphatic tissue in the axillary area. It is of practical use in clinical situations such as breast-conserving surgery combined with SLNB and SLNB after neoadjuvant chemotherapy, because these procedures require the detection of three or more SLNs to accurately determine axillary staging and reduce the false-negative rate.

Injection of MB by INN method can acquire 100% success rate of SLNs detection, which is equivalent to the result of IAA method. This is because of the high degree of lymphatic vessel aggregation in the nipple areola area, and the injection of MB by INN or IAA can converge into the axillary via different lymphatic return pathways, which increases the number of SLNs detected, so from the perspective of detection rate, the INN approach for SLNB is not inferior to the IAA approach.

In conclusion, our experiment is similar to the results reported in the literature and validates the feasibility of the INN approach to MB injection for SLN detection in terms of basic experiments. There is a lack of large scale on prospective clinical trials to validate the advantages and disadvantages of INN of tracers compared to intradermal or subcutaneous injection of tracers.

3.3 Effect of intramammary injection of MB on nipple blood flow

INN with MB had no effect on nipple blood flow in rats, and no nipple necrosis was observed. The maximum possible aesthetic appearance of the breast was ensured. This is of more practical use in clinical situations such as breast-conserving surgery. Therefore, the INN method is an appropriate option for SLN detection. Of course, the results are only validated by animal studies, and more clinical trials are needed to verify the safety of this method.

3.4 Limitations of this experiment

Our experiment also has some limitations, firstly, the lymph nodes resected were not examined pathologically to further clarify the number, but were described based on what was seen morphologically by the naked eye; secondly, the possibility of distant complications was not followed up and needs to be further studied on a large scale. In this paper, the feasibility of this method was firstly verified in rats. Further trials

are still needed to carry out clinical studies of INN with other tracers in the future.

4.CONCLUSION

The injection of MB by INN in rats is feasible to find the sentinel lymph nodes, and the nipple can be one of the injection sites for axillary sentinel lymph node biopsy tracer; INN with MB is safe and reliable.

Funding

1. Beijing Health Promotion Association (2020 CHPASLP-01)
2. Natural Science Foundation of Jilin Province (20200201423JC)
3. Research Fund of the First Institute of Jilin University (2020-CXQ-07)
4. Guiding Fund for Transformation of Achievements of the First Institute of Jilin University
5. Institute of Applied Chemistry (CGZHYD202012-025)
6. Jilin University Project (2021YX0026)

Conflicts of Interest: The authors declare no conflicts of interest.

REFERENCES

1. Clarke D, Khonji NI, Mansel RE. Sentinel node biopsy in breast cancer: ALMANAC trial. *World J Surg.* 2001;25 (6): 819-22. <https://doi.org/10.1007/s00268-001-0011-x>
[PubMed](#), [Scopus](#), [Google Scholar](#)
2. Krag DN, Anderson SJ, Julian TB, Brown AM, Harlow SP, Costantino JP, et al. Sentinel -lymph -node resection with conventional axillary -lymph -node dissection in clinically node-negative patients with breast cancer: overall survival findings from the NSABP B-32 randomised phase 3 trial. *Lancet oncol.*2010;11(10): 927-33. [https://doi.org/10.1016/S1470-2045\(10\)70207-2](https://doi.org/10.1016/S1470-2045(10)70207-2)
[PubMed](#), [Scopus](#), [Google Scholar](#)
3. Lyman GH, Somerfield MR, Bosserman LD, Perkins CL, Weaver DL, Giuliano AE. Sentinel Lymph Node Biopsy for Patients With Early-Stage Breast Cancer: American Society of Clinical Oncology Clinical Practice Guideline Update. *J Clin Oncol.*2017;35(5):561 <https://ascopubs.org/doi/10.1200/JCO.2016.71.0947>
[PubMed](#), [Scopus](#), [Google Scholar](#)
4. Pandya S, Moore RG. Breast development and anatomy. *Clin Obstet Gynecol.* 2011;54 (1):91-5. DOI: 10.1097/GRF.0b013e318207ffe9
[PubMed](#), [Scopus](#), [Google Scholar](#)
5. Zervoudis S, Iatrakis G, Paschopoulos M, Dousias V, Geahchan N, Stefos T, et al. Sentinel lymph node detection by intranipple injection of patent blue dye in breast cancer: a preliminary report of a feasibility study. *Eur J Gynaecol Oncol.* 2012;33(3): 304-5
[View Full Text](#), [PubMed](#), [Scopus](#), [Google Scholar](#)
6. Van den Broeck W, Derore A, Simoens P. Anatomy and nomenclature of murine lymph nodes: Descriptive study and nomenclatory standardization in BALB/cAnNCrl mice. *J Immunol Methods.* 2006;312(1-2): 12-9. <https://doi.org/10.1016/j.jim.2006.01.022>
[PubMed](#), [Scopus](#), [Google Scholar](#)
7. Cruickshank W. The anatomy of the absorbing vessels of the human body. London: Nicol, G;1786. [View Full Text](#), [Google Scholar](#)
8. Sappey PC. Anatomie, physiologie, pathologie des vaisseaux lymphatiques considérés chez l' homme et les vertébrés. (Deuxième partie, comprenant... l'ensemble des planches, etc). Paris1874. 2 parts p. [Google Scholar](#)
9. Turner-Warwick RT. The lymphatics of the breast. *Br J Surg.* 1959;46:574-82 <https://doi.org/10.1002/bjs.18004620004>
[PubMed](#), [Scopus](#), [Google Scholar](#)
10. Suami H, Pan WR, Mann GB, Taylor GI. The lymphatic anatomy of the breast and its implications for sentinel lymph node biopsy: a human cadaver study. *Ann Surg Oncol.* 2008;15 (3): 863-71. DOI: 10.1245/s10434-007-9709-9
[PubMed](#), [Scopus](#), [Google Scholar](#)