

Open Access Article Original Article

## Management of locally advanced breast cancer of the inferior quadrants after neoadjuvant chemotherapy with “B.E.B.A. omelette” Zervoudis oncoplastic technique

S. Zervoudis<sup>1,2,3</sup>, G. Iatrakis<sup>1,2</sup>, G. Papadopoulos<sup>1</sup>, M. Balafouta<sup>2</sup>, T. Chardavelas<sup>1</sup>, A. Bothou<sup>2,4</sup>, I. Navrozoglou<sup>3</sup>, P. Tsikouras<sup>4</sup>, A. Vouxinou<sup>2</sup>, N. Nikolettos<sup>4</sup>, M. Paschopoulos<sup>3</sup>

1. Rea Hospital, Breast Clinic, Athens, Greece.
2. Department of Midwifery & Department of Radiotherapy, University of West Attica (UniWA), Athens, Greece.
3. Faculty of Medicine, University of Ioannina, Ioannina, Greece.
4. Department of Obstetrics and Gynecology, Democritus University of Thrace, Alexandroupolis, Greece.

**Key words:** advanced breast cancer, inferior quadrant breast tumors, oncoplastic surgery, breast cancer surgery

**Citation:** S. Zervoudis, G. Iatrakis, G. Papadopoulos, M. Balafouta, T. Chardavelas, A. Bothou, I. Navrozoglou, P. Tsikouras, A. Vouxinou, N. Nikolettos, M. Paschopoulos. Management of locally advanced breast cancer of the inferior quadrants after neoadjuvant chemotherapy with “B.E.B.A. omelette” Zervoudis oncoplastic technique. *Rev. Clin. Pharmacol. Pharmacokinet.*, Int. Ed. 2021, 35,3, 87-93.

<https://doi.org/10.5281/zenodo.10044385>

Received: 10 December 2021  
Accepted: 24 December 2021  
Republished: 26 October 2023

**Publisher's Note:** PHARMAKON-Press stays neutral with regard to jurisdictional claims in published maps and institutional affiliations.



**Copyright:** © 2023 by the authors.  
Licensee PHARMAKON- Press, Athens, Greece. This article is an open access article distributed under the terms and conditions of the Creative Commons Attribution (CC BY) license. (<http://creativecommons.org/licenses/by/4.0/>).

**Corresponding author:** Prof. Stefanos Zervoudis MD, PhD, Rea Hospital, 383 Syggrou Avenue, Palaio Faliro GR-17564, Greece. *Tel:* +6944308777, *Email:* szervoud@otenet.gr, szervoudis@uniwa.gr

**S u m m a r y:** We present a new technique of oncoplastic surgery for very large tumors of the inferior quadrants of the breast that, after neoadjuvant chemotherapy, allows a good cosmetic result with oncologic safety. This “B.E.B.A. omelette” Zervoudis technique is a mixture of oncoplastic surgery techniques resulting in large excision of breast tissue with a relatively small scar and no complications. More cases could confirm its value in the palette of the oncoplastic methods for large tumors of the inferior quadrants of the breast.

### INTRODUCTION

Large and locally advanced breast cancers cannot be managed first by surgery, because of the technical difficulties and the poor cosmetic results. The concept of neoadjuvant chemotherapy is to reduce dramatically the size of the tumor to facilitate its removal with conservative surgery and avoid mastectomy. Apart from tumor shrinkage (downstaging), neoadjuvant chemotherapy estimates treatment response (Sikov et al 2020) (1)(2) and could act on possible micrometastases to limit the spread of the disease. It seems that the final response to neoadjuvant chemotherapy depends from the initial tumor size (Olatoke et al 2018) (3) and patients with T3 ( $\geq 5$  cm) or T4

lesions were considered “ideal” candidates for this kind of treatment. Moreover this concept could be applied in bicentric tumors in the inferior quadrants (Zervoudis et al 2014) (4).

Neoadjuvant chemotherapy regimens are the same as the standard regimens used after surgery as adjuvant chemotherapy. Regimens most commonly contain an anthracycline (adriamycin or epirubicin) in combination or sequentially administered with taxanes (paclitaxel or docetaxel) (Gamucci et al 2018) (5). To enhance cytotoxicity, anthracycline-based regimens are usually combined with cyclophosphamide with or without the addition of fluoropyrimidines, such as 5-deoxy-fluorouridine. Other drugs that could be used in the neoadjuvant setting are carboplatin and capecitabine. For HER2-positive tumors, neoadjuvant therapy usually includes a combination of chemotherapy and the HER2-targeted therapy drugs trastuzumab (Herceptin) and pertuzumab (Perjeta) (Schneeweiss et al 2013) (6). Although systemic treatment has taken mainly the form of chemotherapy, there is an increasing interest in expanding the role of neoadjuvant endocrine therapy in certain subsets of patients, and also Cyclin-Dependent Kinases inhibitors (CDK) 4/6.

Oncoplastic surgery combines a safe oncological surgical procedure with a very acceptable cosmetic result and neoadjuvant chemotherapy does not increase complications in oncoplastic breast-conserving surgery (Adamson et al 2019) (7). There are many oncoplastic techniques depending on the localization of the tumor (superior external, superior internal, inferior external, inferior internal and central tumors close to the nipple areola complex) and on the experience of the operator :Clough et al 2010(8), Zervoudis et al 2018(9). In particular, the surgical approach of tumors located in the lower quadrant of the breast could result uncertain deformities including the turning down of the nipple areola complex. Nevertheless, this and similar deformities can be avoided with a superior pedicle mammoplasty (and comparable techniques) which allow the removal of a large amount of tissue from the lower pole of the breast. After the removal of the tumor (with a sufficient margin of normal breast tissue and overlying skin), the generated defect is replaced by the midline suture of created medial and lateral glandular columns (aiming to the recentralization of the nipple areola complex). The final surgical result is composed by an inverted T- and periareolar scars: variant technique of Thorek (1922) (10), Pitanguy

(1962) (11) and McKissock (1979) (12),(13). When the tumor is in the medial inferior area 6<sup>th</sup>, 5<sup>th</sup> or 7<sup>th</sup> hour, a large resection could be achieved with a vertical scar and around the areola (Lejour 1994) (14).

The purpose of this study is to describe a new oncoplastic technique aiming to avoid probable deformities after the removal of lower quadrants tumors sized >4 cm managed initially with neoadjuvant chemotherapy. This technique invented by S. Zervoudis [SZ] is a modified variation procedure combining the L and T oncoplastic techniques (8).

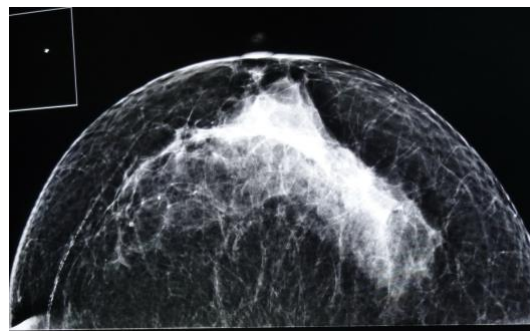


Photo 1 : CC View : large Breast cancer from 5th to 8th left breast, 1cm from the skin.

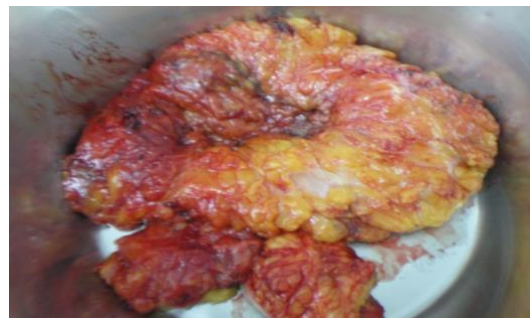

Photo2: Specimen of large lumpectomy sent to the Pathology department.

## MATERIAL AND METHODS

We present our study of twelve cases with locally advanced breast cancer detected in the lower quadrants of the breast and needing neoadjuvant chemotherapy before breast conserving surgery. In nine cases, there was a skin involvement and in three case the distance of the tumor to the skin was almost one mm (Photo 1). However, no tumor was diagnosed as inflammatory breast cancer. In seven cases, the tumor was localized in the inferior internal

quadrant and in five cases in the inferior external quadrant of the breast. The greatest dimension of the tumors included in the study was 16, 14, 13.12, 12, 11, 10, 10, 9, 8, 8 and 7 cm respectively, mean 10.8cm. After neoadjuvant chemotherapy, a reduction of the tumor size of 20 to 80 percent (mean 40 percent) was achieved. The specimen of lumpectomy were sent to the pathological laboratory for complete examination, histological type, grade SBR Nottingham modified, margins, hormonal receptors: RE.RP, cerbB2, P53, Ki67, (Photo 2).

#### **Informed consent**

After a detailed explanation of the prototype technique to the patients (with simple words), a signed consent form was obtained from each one. No patient refused to be operated with this new procedure.

#### **Description of the technique**

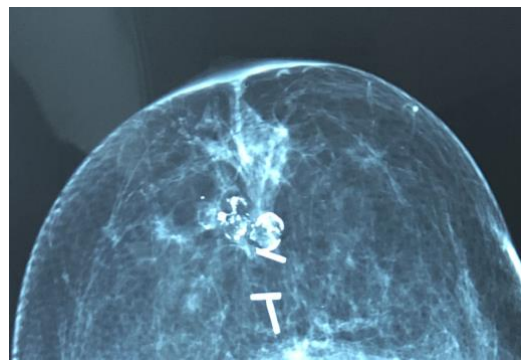
**Objective:** The aim of the technique is to remove the tumor with clear margins: at least 1 cm including the overlying skin (Figure 1).

In general, the margin of normal tissue after the removal of a breast tumor is much narrower than the above mentioned. However, the addition of neoadjuvant chemotherapy (NAC) tends to shrink the tumor. Thus, in order to achieve safe margins, the trend is to increase the distance of normal tissue from the tumor (considering that, before NAC, a part of the tumor was included in this "safe" margin of 1 cm).

Considering the large tumor (even after NAC) and the wide negative margins, the result of the operation after the resection is inevitably a big tissue defect. Thus, the objective of our oncoplastic technique is the tissue reconstruction and the fill of the mentioned defect. Considering the localization of the tumors and that the final scar could be an inverted T or an L or a combination of cosmetically accepted surgical lines, the name **B.E.B.A. (Below Excision for Breast Advanced cancer)** omelet was given to the Zervoudis' technique which is dedicated to Mrs Beba Sardi (see above) because the shape of the incisions was imagined watching a special type of omelet cooked by this lady and created the idea to apply it to the breast incision and the remodeling of the breast after the large excision (see below).

The incision starts about 1 cm from the lower half of the areola circumference and circumscribes the areola in a (outer) circle (dot lines C to D) and the tumor in a trapezoid (dot lines CBED) (Figure 2).

The lower and the upper parts of the outer circle which contains the dots C and D are located about 1 cm and 2 cm far from the lower and the upper part of the areola's perimeter (inner circle), respectively. The areola's perimeter is incised too and the skin between the outer and the inner circles is removed (desepithelization) to allow the ascent of the nipple-areola complex during the reconstruction at the end of the procedure. Regarding the trapezoid CBED, the superior side is very short (less than 2 cm) resulting in a keyhole outline of the incised area, as shown in Figure 1. The exact start point of the incision on the areola (C) depends on the size and the location of the tumor. The two lateral sides of the trapezoid stop at a specific calculated distance from the sub-mammary line. This detail is very important and is one of the keys of the technique because, in that way, we leave a distance between the lower point of the trapezoid and the inferior mammary line to avoid, during the reconstruction with the lateral flaps, the elongation of the final scar downwards (thus creating a bad cosmetic result) and the length of the vertical scar is exact the length of segment III of the breast without extension to segment IV to avoid an unaesthetic scar.



*Photo 3: Mammography one year later: Healing tissue and titanium clips in the previous cancer area*

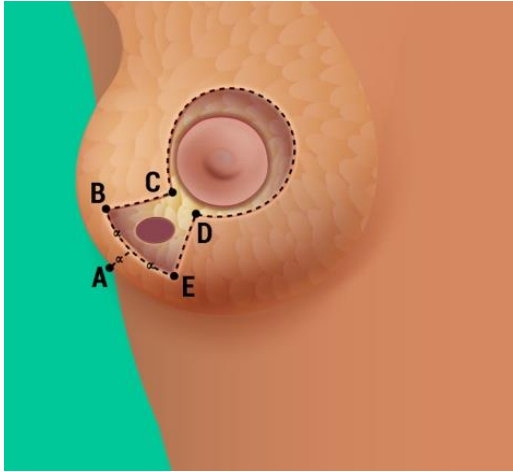


Figure 1. Initial incision including the tumor with clear margins of at least 1 cm.

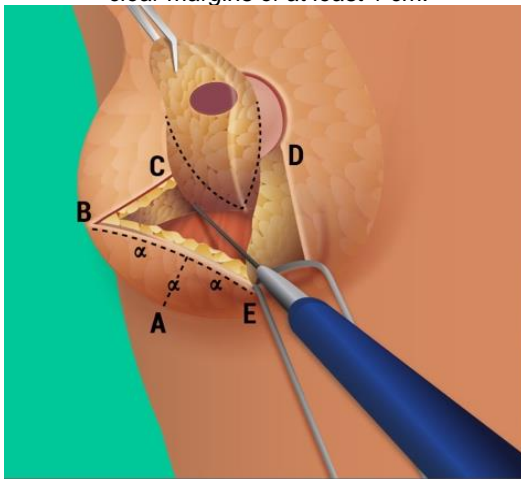


Figure 2. The tumor is included in the trapezoid area C.B.E.D. (which will be removed).

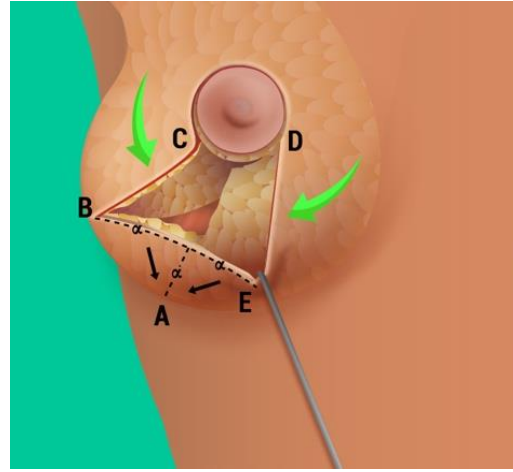


Figure 3. The distance between the middle of the trapezoid's base and the sub-mammary line ( $\alpha$ ), corresponds to the half of the trapezoid's base length ( $2\alpha$ ).

The top angles and the length of the trapezoid's base depend on the size and the location of the tumor. The distance between the middle of the trapezoid's base and the sub-mammary line ( $\alpha$ ), designed as a vertical line on the sub-mammary line (ending on A), corresponds to the half of the trapezoid's base length ( $2\alpha$ ) (Figure 3).

The technique was first tested on animals to assess the best geometry for the incisions. Animal testing showed the previous distance to be optimal. After the experimental surgery on animals, we performed our technique (as training) in patients who were scheduled for mastectomy, starting with the "omelet technique" and ending, during the same surgery, with the classical scheduled mastectomy.

In Figure 2, it is shown the gradual removal of the above-mentioned trapezoid area to a depth reaching the upper surface of the underlying muscle. Thus, the removed trapezoid includes all tissue layers (skin, chorion and breast gland). After a good hemostasis, two clips of titanium are placed in the remaining cavity to guide the future radiotherapy boost (Photo 3). Using a variation of Takeda's technique (Takeda et al 2005) (15), we create two lateral flaps of adipose and fibroglandular tissue which are extended to the middle line cutting them partially as stair step (overlapping of the two flaps). After a mobilization of the upper external part with a length of  $2\alpha$  performing a



rotation to avoid tension, the closure of the trapezoid starts from its top and terminates on its base using an overlap technique in order to fill the defect. Using vicryl 0 for the previous closure, U stitches are placed with the near-far-near technique. We leave a drain only if the hemostasis is not perfect. The skin is sutured with Monocryl 3/0, from the top to the base of the trapezoid, and the connection of the two edges creates a single line which stops vertically exactly at the submammary line (Figure 4).

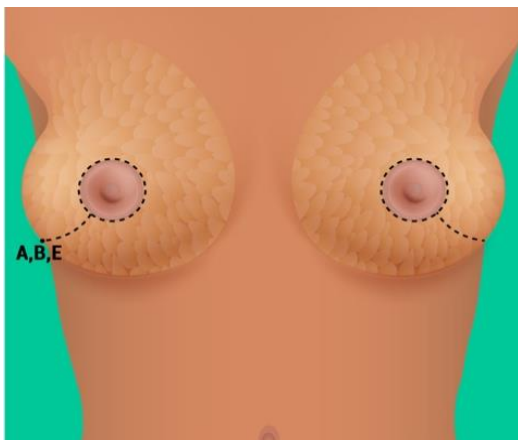


Figure 4. The surgical scar of the removed area including the tumor is a single line ending vertically or oblique to the submammary line. Symmetrization of the contralateral breast.

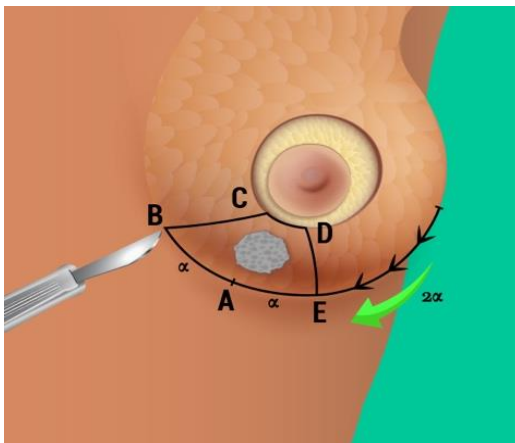


Figure 5. Initial incision including the circumference of the areola and the tumor with clear margins of at least 1 cm extending along the submammary line:  $2\alpha$  to allow the rotation.

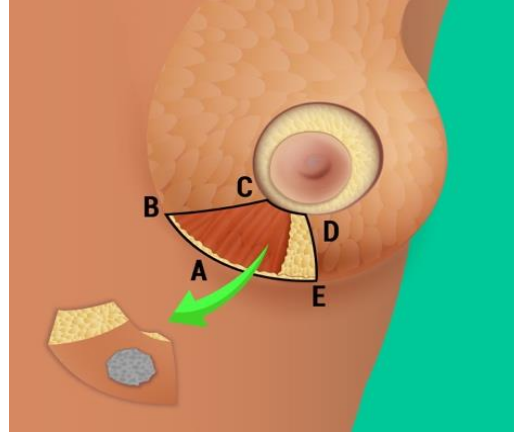


Figure 6. The removed tumor is included in the trapezoid area CBED

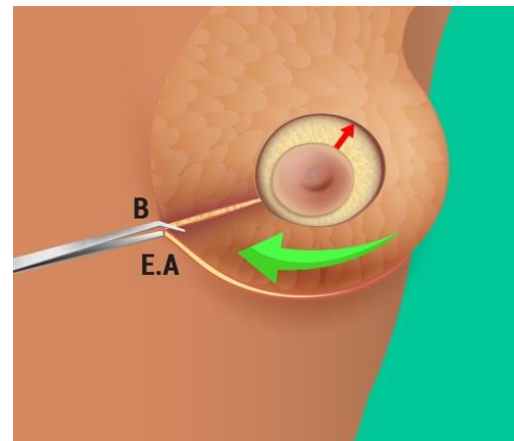


Figure 7. Closure of the removed area after mobilization of adjacent tissue (rotation  $2\alpha$ ) and repositioning of the nipple areola complex upper (red arrow)

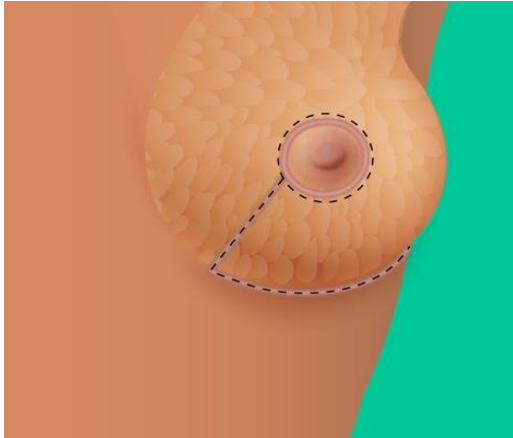


Figure 8. The surgical scar of the removed area including the tumor and mobilized adjacent tissue is a capital L(or J).

The excess skin of the two edges of the basis of the trapezoid (which has become a vertical line) is excised. After creating the above-mentioned straight vertical line, the areola nipple complex is repositioned 1-2 cm higher than its original place with a superior lift to the upper part of the outer circle (circumscribing the areola). The final shape of the suture line is like an "I" joining the areola inferior part to the

Steri-strips are applied on the final scars and a "sport bra" is always worn the ten postoperative days. The patient is discharged from the hospital 4 hours after the completion of the operation with antibiotics and simple painkillers per os.

Per and post-surgery complications (hematoma, infection, division of the scar or nipple areola necrosis) are very rarely observed and did not occur the patients engaged in our study, we noted only two slight hematomas which resolved spontaneously after a few days. Moreover we did not observed any cases of hypoesthesia or hyperesthesia of the nipple.

## DISCUSSION

Oncoplastic techniques for breast surgery are used to resect large tumors with lower re-excision rates compared to standard wide local excisions. These techniques involve a spectrum of local excisions and reconstructions in different quadrants of the breast(8) including the round block technique (Lim et al 2014)(16), modified round block techniques (Refaat et al 2020)(17) and the thoracodorsal flap (Munhoz et al 2006)(18). The modified round block surgery of Zaha et al (2013) (19) uses the periareolar incision as "Benelli round block". However, this technique was used to upper inner, upper outer and upper central tumors that differ from our study's tumors located in the lower quadrants of the breast. Considering that

submammary line (Figure 4). The sentinel node biopsy performed by another incision or axillary dissection and the symmetrization of the contralateral breast completes the surgical procedure (Figure 4).

In tumors located closer to the middle line, although the initial steps of the operation are those described in Figures 1 to 4, the final scar is a capital oblong "J or L".

after neoadjuvant chemotherapy, large tumors could be converted to "small" ones, modified round block techniques for peripherally located tumors were attempted for all quadrants, probably for relatively smaller tumors with a median size of 2 cm (Refaat et al 2020)(17). In the past, a lateral thoracodorsal fasciocutaneous flap was described in immediate conservative breast surgery reconstruction for tumors larger than 4 cm. However, a small percentage of these tumors were located in the lower (outer) quadrants (Munhoz et al 2006)(18). Other options for large tumors of the inferior quadrants are to use a lateral abdominal flap to fill the surgical cavity (after a rotation of 90 degrees) or to use a lateral thoracodorsal flap for breast reconstruction (Holmström & Lossing 1986)(20). However, these procedures are more complicated with moderate cosmetic results. Furthermore, the latter flap was primary used for mastectomy defects. Other oncoplastic procedures for tumors of the inferior quadrants are derivative from plastic reduction techniques, including the Wise pattern breast reduction method (Wise 1956) (21), the inverted T (anchorage) with a superior pedicle (McKissock 1972)(13), the superior pedicle (Weiner et al 1973)(22) and the vertical oncoplasty (Lejour et al 1994) (14) with a lollipop incision. These techniques have some disadvantages in large tumors of the inferior quadrants. As examples, the anchorage technique (McKissock 1972) (13) has large scars and the vertical technique (Lejour et al 1994) (14) do not

remove enough skin. Our technique is a mixture of oncoplastic techniques for the tumors of the inferior quadrant, and is a compromise between safe oncological procedure and good cosmetic result.

### CONCLUSION

We described a new technique of oncoplastic breast surgery for very large tumors or bicentric tumors of the inferior quadrants of the breast which can be used after neoadjuvant chemotherapy when the tumor remains still large. This modified vertical or oblique technique allows a better cosmetic result than the classical techniques of oncoplasty for this type of localization. Moreover, this technique is available for tumors localized in the external inferior or internal inferior quadrants and not only for the middle inferior segment of the breast. Depending of the size of the breast and the size and localization of the remaining tumor, the breast surgeon will have the opportunity to use one more technique on a case-by-case basis. Further studies using our technique should be encouraged to spread it as an alternative surgical procedure in large tumors located in the inferior quadrants of the breast.

**Conflicts of Interest:** The author declares no conflicts of interest regarding the publication of this paper.

### REFERENCES

1. Sikov WM. Choice of neoadjuvant chemotherapy for HER2-negative breast cancer. UpToDate 2020.
2. Sikov WM, Boughey JC, Al-Hilli Z. General principles of neoadjuvant management of breast cancer. UpToDate 2020.
3. Olatoke S, Agodirin O, Rahman G, Habeeb O, Akande H. Relationship between tumour size and response to neoadjuvant chemotherapy among breast cancer patients in a tertiary center in Nigeria. *Malawi Medical Journal* 2018, 30:13-6.
4. Zervoudis S, Iatrakis G, Mares P, Boileau I, Grammatikakis I, Evangelinakis N, Daures JP, Letteuf I, Avgoulea A, Stefanos T, Navrozoglou I. Breast conservative surgery in multicentric breast cancer, preliminary data of our experience. *Eur J Gynaec Oncol* 2014, XXXV, n5, p 530-4.
5. Gamucci T, Pizzuti L, Sperduti I, et al. Neoadjuvant chemotherapy in triple-negative breast cancer: A multicentric retrospective observational study in real-life setting. *J Cell Physiol* 2018, 233:2313-23.
6. Schneeweiss A, Chia S, Hickish T, et al. Pertuzumab plus trastuzumab in combination with standard neoadjuvant anthracycline-containing and anthracycline-free chemotherapy regimens in patients with HER2-positive early breast cancer: a randomized phase II cardiac safety study (Tryphaena). *Ann Oncol* 2013, 24:2278-84.
7. Adamson K, Chavez-MacGregor M, Caudle A, et al. Neoadjuvant Chemotherapy does not Increase Complications in Oncoplastic Breast-Conserving Surgery. *Ann Surg Oncol* 2019, 26:2730-7.
8. Clough KB, Kaufman GJ, Nos C, Buccimazza I, Sarfati M. Improving Breast Cancer Surgery: A Classification and Quadrant per Quadrant Atlas for Oncoplastic Surgery. *Ann Surg Oncol* 2010, 7:1375-91.
9. Zervoudis S, Iatrakis G, Bothou A, Peitsidis P, Fotopoulos S, Navrozoglou I, Pasxopoulos M, Stefanos T. Clinical feasibility of a new oncoplastic technique for breast lumps of the external quadrants: half moon lateral crescent technique. *Clin Exp Obstet Gynecol* 2018, XLV, n 3, p 347-52.
10. Thorek M. Possibilities in the reconstruction of the human form. *Med J Rec* 1922, 116:572-3.
11. Pitanguy I. Une nouvelle technique de plastie mammaire. *Ann. Chir Plast* 196, 7:199.
12. McKissock PK. Reduction mammoplasty. *Ann Plast Surg* 1979, 2:321-31.
13. McKissock PK. Reduction mammoplasty with a vertical dermal flap. *Plast Reconstr Surg* 1972, 49:245-52.
14. Lejour M. Vertical mammoplasty and liposuction of the breast. *Plast Reconstr Surg* 1994, 94:100-14.
15. Takeda M, Ishida T, Ohnuki K, Suzuki A, Kiyohara H, Moriya T, Ohuchi N. Breast conserving surgery with primary volume replacement using a lateral tissue flap. *Breast Cancer* 2005, 12:16-20.
16. Lim G-H, Allen JC, Ruey Ng RP. Oncoplastic round block technique has comparable operative parameters as standard wide local excision: a matched case-control study. *Gland Surg* 2017, 6:343-9.
17. Refaat M, Abouelnagah G, Awad AT, Fayed HM, Abdelhady DA. Modified round block technique for peripherally located early cancer breast, a technique that fits for all quadrants. *Breast J* 2020, 4:414-9.
18. Munhoz AM, Montag E, Arruda EG, Aldrighi C, Gemperli R, Aldrighi JM, Ferreira MC. The role of the lateral thoracodorsal fasciocutaneous flap in immediate conservative breast surgery reconstruction. *Plast Reconstr Surg* 2006, 117:1699-70.
19. Zaha H, Onomura M, Uresoko M. A new scarless oncoplastic breast-conserving surgery: Modified round block technique. *The Breast* 2013, 2:1184-8.
20. Holmström H, Lossing C. The lateral thoracodorsal flap in breast reconstruction. *Plast Reconstr Surg* 1986, 77:933-43.
21. Wise RJ. A preliminary report on a method of planning the mammoplasty. *Plast Reconstr Surg* 1956, 17:367-75
22. Weiner DL, Aiache AE, Silver L, Tittiranonda T. A single dermal pedicle for nipple transposition in subcutaneous mastectomy, reduction mammoplasty, or mastopexy. *Plast Reconstr Surg* 1973, 51:115-20